

Case Report: Immune-mediated Complete Response in a Patient With Recurrent Advanced Ewing Sarcoma (EWS) After Vigil Immunotherapy

Maurizio Ghisoli, MD,*†‡ McCarley Rutledge,* Philip J. Stephens,§
 Robert Mennel, MD,† Minal Barve, MD,*† Meghan Manley,* Bahram R. Oliai, MD,||
 Kathleen M. Murphy, MD,|| Luisa Manning, MD,¶ Belen Gutierrez,*
 Priyanka Rangadass,* Ashli Walker,* Zhaohui Wang,# Donald Rao,# Ned Adams,*
 Gladice Wallraven,¶ Neil Senzer, MD,*¶# and John Nemunaitis, MD*†‡¶#

Summary: Ewing sarcoma is a highly resistant disease with a < 10% chance of survival at 5 years after failure of frontline chemotherapy. This is a case report of an Ewing sarcoma patient with metastatic disease recurrence < 2 years after standard chemotherapy/radiation who achieved a durable and sustained complete response after 2 series of treatments with Vigil (*GMCSF/bi-shRNA^{furin}* DNA autologous tumor immunotherapy) serially manufactured from first and second recurrences with ELISPOT assay correlation. Results support justification of further testing of Vigil with ELISPOT assay as a biomarker to assess level of immune response and correlation with disease control.

Key Words: Ewing sarcoma, Vigil, immunotherapy

(*J Pediatr Hematol Oncol* 2017;39:e183–e186)

BACKGROUND

Ewing sarcoma (EWS) is an aggressive, poorly differentiated tumor of the bone and soft tissue driven by the *EWS/FLI1* (*t*_{11;22} [q24;q12]) gene fusion in 85% of cases with an incidence of 2.9 per million cases in the United States. Approximately 30% to 40% of patients develop recurrent local or metastatic disease after frontline treatment with aggressive chemotherapy. Recurrent disease is associated with a poor prognosis with a 5-year survival of 10% to 25%.^{1,2} Prognosis is particularly poor when recurrence develops within 2 years of chemotherapy initiation (5 y survival < 10%).

Recently, we have published clinical phase I data that provide evidence of immune biomarker and associated clinical response to Vigil, a novel *bi-shRNA^{furin}* (*bi-shRNA^{furin}*)/*GMCSF* DNA engineered autologous whole tumor cell immunotherapy, in patients with advanced disease EWS.³ Others have also reported the effectiveness of immunotherapeutic approaches to relapsed/metastatic EWS (eg, progressive disease-1 inhibition; tumor lysate

dendritic cell vaccine) by demonstrating clinical response and improved outcome.⁴ Herein we report a unique case of immune induction and presumptive prolonged memory cell persistence following second-line and third-line treatment with Vigil,^{3,5} a *GMCSF/bi-shRNA^{furin}* DNA expressive autologous tumor immunotherapy, in a high-risk patient with widespread metastatic EWS who experienced recurrence within 2 years of combined modality chemotherapy and radiation.

MATERIALS AND METHODS

Design

This analysis involves a case report of a patient (#062) entered into a phase I trial⁵ of intradermal Vigil at 1×10^7 cells/injection administered monthly for a minimum of 4 months. #062 was managed in an outpatient setting at Mary Crowley Cancer Research. Hematologic function, liver enzymes, renal function, and electrolytes were monitored monthly. Serial immune function analysis including interferon- γ ELISPOT analysis^{3,5} of peripheral blood mononuclear cell function to preprocessed autologous tumor cells was performed at baseline (screening), before Vigil injection and at months 2, 4, 6, end of treatment, and at follow-up. A positive response was defined as > 10 ELISPOTs induced per 5×10^3 peripheral blood mononuclear cells and $\geq 2 \times$ baseline. Physical examination, performance status, height, weight, temperature, blood pressure, pulse, and toxicity were monitored.

Tumor Procurement/Vigil Manufacturing

Gradalis Inc. (Carrollton, TX) manufactured Vigil from tumor procured during resection of a 1.0×0.8 cm lung mass. Manufacturing was a 2-day process (product release 3 wk). Preoperative radiologic scans were required to confirm the presence of a lesion before resection.⁵

Investigational Product

Vigil is made up of irradiated autologous tumor cells previously electroporated ex vivo with the Vigil plasmid expressing *rhGMCSF* protein and a bifunctional shRNA targeting the pro-protein convertase furin so as to simultaneously suppress expression of both transforming growth factor (*TGF*) β 1 and *TGF* β 2 immunosuppressive proteins.⁵ Tumor was collected on site at the surgical debulking procedure to confirm recurrence and placed in sterile saline then packaged for transport to the manufacturing facility

Received for publication November 2, 2016; accepted February 27, 2017.

From the *Mary Crowley Cancer Research Centers; †Texas Oncology, P.A.; ‡Medical City Dallas Hospital; ||ProPath; ¶Gradalis Inc.; #Strike Bio, Dallas, TX; and §Foundation Medicine, Cambridge, MA.

The following authors are shareholders in Gradalis Inc. and Strike Bio: Z.W., D.R., G.W., N.S., and J.N. The authors declare no conflict of interest.

Reprints: John Nemunaitis, MD, 12222 Merit Drive, Suite 1500, Dallas, TX 75251 (e-mail: jnemunaitis@marycrowley.org).

Copyright © 2017 Wolters Kluwer Health, Inc. All rights reserved.

where the tumor was mechanically and enzymatically dissociated into a single cell suspension. The cells were counted and then transfected with the Vigil plasmid through electroporation. After plasmid transfer, the cells were washed and irradiated within 24 hours at 10 Gy (irradiator). The irradiated cell suspension was then enumerated, aliquoted, and frozen (1×10^7 cells per vial). The freeze media consists of 10% dimethyl sulfoxide (Cryoserv USP; Bionichepharma US), 1% human serum albumin (ABO Pharmaceuticals) in Plasma-Lyte A at pH 7.4 (Baxter). After freezing the cells were stored in the vapor phase of liquid nitrogen. The product is released for administration once release criteria are met (generally within 3 wk).

CASE PRESENTATION

#062 presented with left hip and leg pain at age 15. Computerized tomography (CT) scan identified a mass in her pelvic region. Staging by magnetic resonance imaging scan, bone scan and positive FDG-PET (maximum SUV 3.6) showed widely metastatic disease involving the lower abdomen (8 cm pelvic mass), bone (pelvis, T11, and L4), and lung. A core tumor biopsy showed tumor composed of small blue cell tumor with necrosis consistent with EWS and chromosomal analysis confirmed the presence of the pathognomonic *EWS/FLII* $t_{11;22}$ translocation. The patient was treated with vincristine/actinomycin and cyclophosphamide/ifosfamide/etoposide and local intensity-modulated radiation therapy to her left pelvis and L4, as well as whole lung radiation with boost (35 Gy) to T11. During frontline chemotherapy she experienced several grade 3 adverse events and was hospitalized multiple times for chemotherapy-related toxicity. Imaging assessment at completion of treatment demonstrated no evidence disease confirming a complete response. However, <24 months after initial treatment, follow-up imaging identified recurrent disease in multiple lobes of the lung. Shortly afterwards, following Mary Crowley Cancer Research Investigational Review Board approved informed consent, she underwent thoracoscopic surgery with removal of a progressive lesion from which 8 vials of Vigil with a unit dose of 1×10^7 cells/mL were manufactured (Gradalis Inc.). A tissue specimen also was sent for *EWS/FLII* type 1 sequence analysis, which identified the EWS exon 7-*FLII* exon 6 fusion gene (Strike Bio, Carrollton, TX). Immune response was assessed by modified interferon- γ ELISPOT assays^{3,5} at baseline before Vigil and at sequential time points during and after completion of Vigil. Her baseline ELISPOT assay was negative. She received her first cycle of Vigil as part of a phase I trial 1 month later. A positive ELISPOT response (from a baseline of 0 to 93 spots/ 5×10^3 cells read independently by ZellNet Consulting Inc., NJ) was first noted at the end of month 2. All 8 cycles of Vigil were well tolerated and there were no \geq grade 3 adverse events. By the end of treatment she achieved stable disease (SD) by RECIST 1.1 criteria. A CT scan at 1-year follow-up demonstrated SD of the target lesions in her lungs and immunoassay showed a durable positive ELISPOT response. These results persisted for over 18 months (Fig. 1) at which time CT imaging revealed increase in size of multiple lung lesions. In addition, serial immune biomarker testing had shown a significant decrease in ELISPOT count (Fig. 1) just before imaging confirmation of progressive disease.

Twenty months after her first Vigil immunotherapy construction she underwent a second tissue procurement of an expanding lung lesion as part of phase I trial for

manufacture of a second Vigil immunotherapy. Six doses were produced. Pathology reconfirmed EWS identifying malignant cells (small blue cell tumor) and *CD99*, *FLII*, *NKX2.2* positive immunohistochemistry identical to the original pathology. Next generation sequencing analysis (Foundation Medicine, Boston, MA) of this specimen showed a low tumor mutation burden (TMB) of 3 mutations per Mb and reconfirmed the *EWSR1* fusion that was also evaluated by reverse transcription-polymerase chain reaction. Fluorescent in situ hybridization for each end of the *EWSR1* gene in chromosome band 22q12 (192 of 200 [96%] nuclei showed separation of the signals; consistent with chromosome rearrangement at band 22q12) (ProPath, Dallas, TX) and a new molecular signal involving *CAD* rearrangement at intron 35 was identified. However, mutations of *CIITA*, *FBXO11*, *FLYWCHI*, *HIST1H1C*, *MKI67*, and *PLCG2* identified in the original Ewing sample were not present in the second Vigil immunotherapy sample.

#062 then received a second series of 6 treatments of Vigil without adverse event other than grade 1 to 2 erythema and swelling at the injection site at cycle 4. The baseline ELISPOT before the second treatment series was 15 spots/ 5×10^3 cells. One month after cycle 1 the ELISPOT increased to 115 spots/ 5×10^3 cells against the pre-processed sarcoma cells from the second harvest and has remained above threshold throughout her subsequent follow-up visits (Fig. 1). Her first postsecond series Vigil follow-up CT scan (1 mo after end of treatment) showed no evidence of active disease with only persistent, stable, subcentimeter nodules (1 to 2 mm) that were present at her original presenting scans and consistent with benign granulomas. At 10 months after the second tissue procurement and 3.5 years from her first recurrence #062 continues without evidence of active disease by both CT scan and PET scan (Fig. 2). She has not received any anticancer treatment other than Vigil.

In summary, we present a patient with *EWS/FLII* type 1 EWS who sequentially achieved a rarely seen immunotherapy induced classically defined complete responses (to both first and second recurrences) following Vigil. Circulating ELISPOT reactive T cells were induced by treatment with Vigil and serial assays correlated with the patient's clinical course.

DISCUSSION

The case history of #062 illustrates the effectiveness of a unique immunotherapeutic and the potential utility of immune biomarker patterns. After initial treatment with Vigil, the patient experienced a SD status more durable than what would have been predicted based on historical data. Then, nearly a year after completion of the second series Vigil treatments, she achieved a clinical and CT/PET complete response that correlated with serial ELISPOT assays, a biomarker response that has previously been shown to correlate with survival following Vigil treatment.^{3,5-7} Moreover, this response was achieved without toxic side effects. The persistence of activated T-cell levels for 13 months after completion of Vigil treatment #1 and for 10+ months after completion of Vigil treatment #2 is suggestive of and consistent with the presumptive induction of durable memory T cells. In the absence of T-cell phenotyping the kinetics of memory T-cells subtypes cannot be delineated nor the relative numbers of central memory (T_{cm}; CD62L⁺/

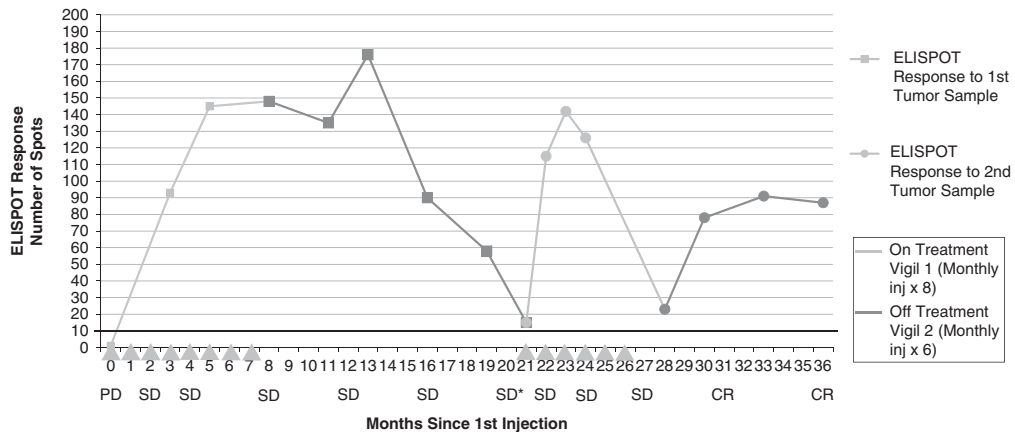


FIGURE 1. Interferon- γ ELISpot expression of #062 treated with Vigil from baseline and after the first (yellow curve representing treatment, gray line for off-treatment) and second (yellow curve representing treatment, gray line for off-treatment) treatment course with Vigil. The squares demonstrate each injection of first treatment with Vigil; circles for second treatment with Vigil. The y-axis represents the (mean) number of spots counted on the ELISpot microplate after exposure of cancer cells to mononuclear cells from patient. Disease responding computerized tomography (CT) scan and CT/PET scan are labeled as progressive disease (PD), standard disease (SD), or complete response (CR). *Multiple expanding lung lesions <20%, largest lesion harvested for vaccine.

CCR7⁺) and effector memory (Tem) (CD62L⁻/CCR7⁻) T cells be ascertained. However, in so far as *TGF β 1* has been shown to suppress the acquisition of T-cell effector memory functionality at initial antigen activation,⁸ induction of Tem consequent to the >90% *TGF β 1*, *TGF β 2* downregulation effected by the *bi-shRNA^{furin}* component of Vigil is a reasonable hypothesis. It is likely that the dominant neoantigen target of the first Vigil vaccine was related to the *EWS/FLI1* type 1 fusion protein, as suggested by Peng et al⁹ in the *EWS/FLI1* peptide-pulsed dendritic cell-treated xenograft response and in vitro analysis, particularly given the low TMB of EWS patients in general and of #062 in particular.¹⁰⁻¹² It is typically a high TMB that is associated with a higher probability of functional neoantigens which have not been subject to central processing. CT scan and PET scan reversion to negative status following the second series Vigil therapy suggests a complete immunologic clearance of *EWS/FLI1* expressive cells. The emergence of an *EWS/FLI1* subclone with loss of the *CIITA*, *FBXO11*, *FLYWCH1*,

HIST1H1C, *MKI67*, and *PLCG2* mutations and emergence of *CAD* rearrangement as a result of clonal competition or allopatric speciation in a therapeutically altered immune environment,^{13,14} or the occurrence of clonal divergence before diagnosis may explain the altered genotype following the first Vigil course. This could also be consistent with shifting neoantigen landscape dynamics under T-cell pressure¹⁵ or intertumoral molecular heterogeneity as has been previously reported in EWS (albeit infrequently).¹⁶ These considerations will inform future studies with Vigil.

To our knowledge this is the first reported case of an immunotherapy-mediated complete response with biomarker correlate in an EWS patient with progressive and metastatic recurrent disease. ELISpot assays have been used by others as well and have shown correlation with clinical benefit.¹⁷⁻²⁰ The current results accord with these reports and emphasize the need to monitor both the somatic genetic changes in cancers, particularly at the time of postimmunotherapy recurrence, and the necessity of expanding immune biomarker

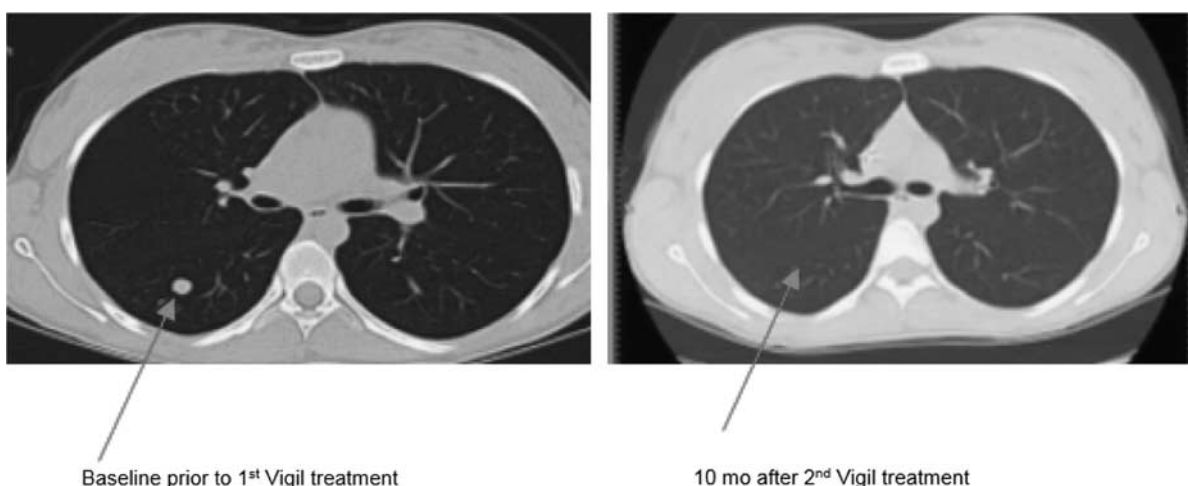


FIGURE 2. Computerized tomography (CT) scan highlighting one of several progressive pulmonary lesions before first Vigil treatment compared with first CT scan representing complete response 10 months after second Vigil treatment was initiated.

assays to further define those immune effectors associated with effective, durable immune responses. Clearly, such information could contribute to the design of more effective event-specific immunotherapeutics.

We are currently exploring further molecular/immune testing methodology to delineate the mechanics and cellular phenotype of Vigil-induced immune response and to determine the patterns of immune response kinetics in relation to shifting antigen landscape dynamics so as to better optimize therapy. Randomized testing of Vigil in advanced EWS is ongoing at several sites across the country (NCT02511132).

ACKNOWLEDGMENTS

The authors thank the generous support of the Jasper L. and Jack Denton Wilson Foundation, Speedway Children's Charities, the Summerfield G. Roberts Foundation, the Rutledge Foundation, Triumph Over Kid Cancer, Wipe Out Kids' Cancer and Young Texans Against Cancer. The authors would like to acknowledge Michelle Watkins and Brenda Marr for their competent and knowledgeable assistance in the preparation of the manuscript.

REFERENCES

- Bacci G, Ferrari S, Longhi A, et al. Therapy and survival after recurrence of Ewing's tumors: the Rizzoli experience in 195 patients treated with adjuvant and neoadjuvant chemotherapy from 1979 to 1997. *Ann Oncol*. 2003;14:1654–1659.
- Barker LM, Pendergrass TW, Sanders JE, et al. Survival after recurrence of Ewing's sarcoma family of tumors. *J Clin Oncol*. 2005;23:4354–4362.
- Ghisoli M, Barve M, Mennel R, et al. Three-year follow up of GMCSF/bi-shRNA(furin) DNA-transfected autologous tumor immunotherapy (Vigil) in metastatic advanced Ewing's sarcoma. *Mol Ther*. 2016;24:1478–1483.
- McCaughan GJ, Fulham MJ, Mahar A, et al. Programmed cell death-1 blockade in recurrent disseminated Ewing sarcoma. *J Hematol Oncol*. 2016;9:48.
- Senzer N, Barve M, Nemunaitis J, et al. Long term follow up: phase I trial of "bi-shRNA furin/GMCSF DNA/autologous tumor cell" immunotherapy (FANG™) in advanced cancer. *J Vaccines Vaccin*. 2013;4:209.
- Oh J, Barve M, Matthews CM, et al. Phase II study of Vigil(R) DNA engineered immunotherapy as maintenance in advanced stage ovarian cancer. *Gynecol Oncol*. 2016;143:504–510.
- Barve M, Kuhn J, Lamont J, et al. Follow-up of bi-shRNA furin/GM-CSF engineered autologous tumor cell (EATC) immunotherapy Vigil® in patients with advanced melanoma. *Biomed Genet Genomics*. 2016;1:81–86.
- Ahmadzadeh M, Rosenberg SA. TGF-beta 1 attenuates the acquisition and expression of effector function by tumor antigen-specific human memory CD8 T cells. *J Immunol*. 2005;174:5215–5223.
- Peng W, Huang X, Yang D. EWS/FLI-1 peptide-pulsed dendritic cells induces the antitumor immunity in a murine Ewing's sarcoma cell model. *Int Immunopharmacol*. 2014;21:336–341.
- Lawrence MS, Stojanov P, Polak P, et al. Mutational heterogeneity in cancer and the search for new cancer-associated genes. *Nature*. 2013;499:214–218.
- Rizvi NA, Hellman MD, Snyder A, et al. Cancer immunology. Mutational landscape determines sensitivity to PD-1 blockade in non-small cell lung cancer. *Science*. 2015;348:124–128.
- Rosenberg JE, Hoffman-Censits J, Powles T, et al. Atezolizumab in patients with locally advanced and metastatic urothelial carcinoma who have progressed following treatment with platinum-based chemotherapy: a single-arm, multicentre, phase 2 trial. *Lancet*. 2016;387:1909–1920.
- McGranahan N, Favero F, de Bruin EC, et al. Clonal status of actionable driver events and the timing of mutational processes in cancer evolution. *Sci Transl Med*. 2015;7:283ra54.
- McGranahan N, Swanton C. Biological and therapeutic impact of intratumor heterogeneity in cancer evolution. *Cancer Cell*. 2015;27:15–26.
- Verdegaal EM, de Miranda NF, Visser M, et al. Neoantigen landscape dynamics during human melanoma-T cell interactions. *Nature*. 2016;536:91–95.
- Bielack SS, Paulussen M, Kohler G. A patient with two Ewing's sarcomas with distinct EWS fusion transcripts. *N Engl J Med*. 2004;350:1364–1365.
- Malyguine A, Strobl SL, Shafer-Weaver KA, et al. A modified human ELISPOT assay to detect specific responses to primary tumor cell targets. *J Transl Med*. 2004;2:9.
- Kirkwood JM, Lee S, Moschos SJ, et al. Immunogenicity and antitumor effects of vaccination with peptide vaccine + γ -granulocyte-macrophage colony-stimulating factor and/or IFN- α 2b in advanced metastatic melanoma: Eastern Cooperative Oncology Group Phase II Trial E1696. *Clin Cancer Res*. 2009;15:1443–1451.
- Gulley JL, Arlen PM, Madan RA, et al. Immunologic and prognostic factors associated with overall survival employing a poxviral-based PSA vaccine in metastatic castrate-resistant prostate cancer. *Cancer Immunol Immunother*. 2010;59:663–674.
- Disis ML, Wallace DR, Gooley TA, et al. Concurrent trastuzumab and HER2/neu-specific vaccination in patients with metastatic breast cancer. *J Clin Oncol*. 2009;27:4685–4692.